

Περιοδικό της Ελληνικής Κτηνιατρικής Εταιρείας

Τόμ. 70, Αρ. 1 (2019)



Αμφοτερόπλευρη νεοπλασία - επιθηλίωμα μείβομιανών αδένων των βλεφάρων σε σκύλο

A. KOMNENOU, G. CHARALAMBIDOU, S.
MAKROGKIKAS, N. PAPAIOANNOU

doi: [10.12681/jhvms.20352](https://doi.org/10.12681/jhvms.20352)

Copyright © 2019, A. KOMNENOU, G. CHARALAMBIDOU, S.
MAKROGKIKAS, N. PAPAIOANNOU



Άδεια χρήσης [Creative Commons Αναφορά-Μη Εμπορική Χρήση 4.0](https://creativecommons.org/licenses/by-nc/4.0/).

Βιβλιογραφική αναφορά:

KOMNENOU, A., CHARALAMBIDOU, G., MAKROGKIKAS, S., & PAPAIOANNOU, N. (2019). Αμφοτερόπλευρη νεοπλασία - επιθηλίωμα μείβομιανών αδένων των βλεφάρων σε σκύλο. *Περιοδικό της Ελληνικής Κτηνιατρικής Εταιρείας*, 70(1), 1435–1442. <https://doi.org/10.12681/jhvms.20352>

Bilateral primary eyelid meibomian gland epithelioma in a dog: a case report.

A. Komnenou,¹ G. Charalambidou,¹ S. Makrogkikas,¹ N. Papaioannou²

*¹Clinic of Companion Animals, School of Veterinary Medicine, Faculty of Health Sciences, Aristotle University
of Thessaloniki, Greece*

*²Laboratory of Pathology, School of Veterinary Medicine, Faculty of Health Sciences, Aristotle University of Thessaloniki,
Greece*

ABSTRACT. In this paper an extremely rare case of primary bilateral eyelid meibomian gland epithelioma in a dog is presented. Meibomian tumors arise from the meibomian (tarsal) glands on the inner aspect of the eyelid, and meibomian gland adenomas and adenocarcinomas are the most frequent neoplasia arising from those glands. A 10-year-old male dog was admitted, with ophthalmic signs of periorbital swelling of the right eye. During the last two years, the dog had a progressive engorgement of the upper eyelid of the right eye, and during the past few months, strabismus and exophthalmos were also noticed, as well as a slighter enlargement on the lower eyelid of the left eye. Upon ophthalmic examination strabismus and periorbital swelling at the lateral canthus of the right eye, accompanied by mild exophthalmos and lagophthalmos, were recorded. Also, deep ulcerative keratitis with corneal oedema and neovascularization were noticed. Intense chemosis, epiphora and a small pinkish mass arising from the palpebral conjunctiva of the left lower eyelid were also seen. Neoplasia of both eyelids was suspected, and a series of diagnostic examinations were carried out. Orbital exenteration of the right eye was performed in the first place, followed by surgical removal of the mass of the left eyelid one month later. Based on clinical and histopathological findings, meibomian gland epithelioma was diagnosed. No relapse or metastases (local or distant) were observed in re-examinations within 18 months after the surgery. This study shows that although meibomian gland epithelioma is rare, it should be considered in the differential diagnosis of cases of orbital and eyelid tumors. Even though this tumor shows low malignancy, prompt surgical intervention and extended excision is the treatment of choice, in order to preserve vision in some cases. To the authors'

Corresponding Author:
Charalambidou Glykeria
11 Stavrou Voutira Street, 54627, Thessaloniki, Greece
Email address: glykcharala@hotmail.com

Date of initial submission: 4/2/2018
Date of revised submission: 29/5/2018
Date of acceptance: 4/6/2018

knowledge, the present case is the first report of bilateral meibomian gland epithelioma in the veterinary literature.

Keywords: Bilateral eyelid tumor, meibomian epithelioma, tarsal tumor, eyelid, dog.

ΠΕΡΙΛΗΨΗ. Σε αυτή την εργασία γίνεται αναφορά σε ένα σπάνιο κλινικό περιστατικό με αμφοτερόπλευρο πρωτογενές επιθηλίωμα των μείβομιανών αδένων σε σκύλο. Οι νεοπλασίες των μείβομιανών (ταρσαίων) αδένων προέρχονται από τη βάση των αδένων αυτών, στον ταρσό του βλεφάρου. Τα αδενώματα και τα αδενοκαρκινώματα αποτελούν τις συχνότερες νεοπλασίες των ταρσαίων αδένων. Σκύλος, αρσενικός, ηλικίας 10 ετών, προσκομίστηκε με μία περιοφθαλμική διόγκωση στο άνω βλέφαρο του δεξιού οφθαλμού που τα τελευταία δύο χρόνια αναπτυσσόταν σταδιακά, ενώ στον αριστερό οφθαλμό παρατηρήθηκε από τον ιδιοκτήτη μία μικρότερη διόγκωση στο κάτω βλέφαρο του αριστερού οφθαλμού. Κατά την οφθαλμολογική εξέταση διαπιστώθηκε στραβισμός, περιοφθαλμική διόγκωση στον έξω κανθό του δεξιού οφθαλμού, που συνοδευόταν από ήπιο εξόφθαλμο και λαγόφθαλμο. Παράλληλα υπήρχε εν τω βάθει ελκώδης κερατίτιδα, με οίδημα και νεοαγγείωση στον κερατοειδή. Στον αριστερό οφθαλμό διαπιστώθηκε έντονη χύμωση, επιφορά και η παρουσία μίας μάζας που προερχόταν από τον επιπεφυκότα του κάτω βλεφάρου. Με βάση την κλινική εικόνα τέθηκε υποψία νεοπλάσματος και στους δύο οφθαλμούς και διενεργήθηκαν διάφορες διαγνωστικές εξετάσεις. Στη συνέχεια έγινε εξόρυξη του δεξιού οφθαλμού και ένα μήνα μετά ακολούθησε χειρουργική αφαίρεση της μάζας του αριστερού οφθαλμού. Με βάση την κλινική και την ιστοπαθολογική εικόνα του περιστατικού, τέθηκε η διάγνωση του επιθηλιώματος των μείβομιανών αδένων. Σε επανεξετάσεις που έγιναν μέχρι και 18 μήνες μετά δεν παρατηρήθηκε υποτροπή, ούτε διαπιστώθηκαν επιχώριες ή απομακρυσμένες μεταστατικές εστίες. Το επιθηλίωμα των μείβομιανών αδένων, αν και σπάνιο, θα πρέπει να συμπεριλαμβάνεται στη διαφορική διάγνωση των όγκων του οφθαλμικού κόγχου και των βλεφάρων. Αν και οι μεταστάσεις είναι σπάνιες, η έγκαιρη χειρουργική εξαίρεση αποτελεί την θεραπεία εκλογής, προκειμένου να διατηρηθεί ο βολβός και η όραση σε κάποιες περιπτώσεις. Στην παρούσα εργασία γίνεται αναφορά για πρώτη φορά σε αμφοτερόπλευρο επιθηλίωμα των μείβομιανών αδένων.

Λέξεις ευρετηρίασης: Αμφοτερόπλευρη νεοπλασία βλεφάρων, επιθηλίωμα μείβομιανών αδένων, νεοπλασία ταρσαίων αδένων, βλέφαρο, σκύλος.

INTRODUCTION

Eyelid tumors, although infrequent in the domestic species, are of major consideration when it comes to periorbital proliferative swellings. The most frequent canine eyelid neoplasms involve meibomian gland adenoma, squamous papiloma, meibomian adenocarcinoma, melanoma (benign and malignant), histiocytoma, mastocytoma, basal cell carcinoma, squamous cell carcinoma, fibroma, fibropapilloma, lipoma and others (Krehbiel and Langham, 1975; Roberts et al., 1986). Studies have shown that epithelial tumors seem to be more prevalent than the tumors of mesenchymal origin (Krehbiel and Langham, 1975). Most of the eyelid tumors in dogs are locally minimally invasive (Frans and van der Woerd, 2013). In addition, several retrospective studies suggest that the majority of the eyelid tumors (73.3%-87.8%) proved to be benign (Krehbiel and Langham, 1975; Roberts et al., 1986), however,

malignant tumors often recurred locally but did not have a high frequency of metastasis (Krehbiel and Langham, 1975).

Meibomian tumors arise from the meibomian (tarsal) glands on the inner aspect of the eyelid (Maggs, 2007), and meibomian gland adenomas and adenocarcinomas are the most frequent neoplasia arising from those glands (Krehbiel and Langham, 1975; Roberts et al., 1986). Benign meibomian gland tumors present as focal or multifocal nodular masses. A meibomian gland adenoma is made up of fully differentiated meibomian glandular tissue, including the holocrine secretory cells and the keratinizing ducts. On the other hand, meibomian gland epitheliomas consist of poorly differentiated basal cells and rarely show sebaceous or squamous differentiation. Similarly, epitheliomas are more likely to be pigmented and they are slightly larger and probably located deeper in the lid margin dermis than adenomas. Eyelid tumors in general, may cause problems related to their contact with

the corneal surface causing irritation, or may be considered a cosmetic problem (Dubielzig et al., 2010). Advanced meibomian adenomas or adenocarcinomas may ulcerate or hemorrhage. Also, local irritation resulting in blepharospasm, epiphora, conjunctival hyperemia, corneal vascularization, and pigmentation are reported. Therefore, early surgical removal of eyelid tumors is the treatment of choice (Frans and van der Woerd, 2013).

The dog described in this report is an extremely rare case with bilateral primary meibomian gland epithelioma. To the authors' knowledge, there is no similar case reported in the veterinary literature.

CASE HISTORY

A 10-year old spayed, crossbreed, male dog was presented to the Comparative Ophthalmology Unit of the Companion Animal Clinic, School of Veterinary Medicine, Aristotle University of Thessaloniki, with ophthalmic signs of exophthalmos of the right eye and mild swelling of the lower eyelid of the left eye. According to the owner, during the last two years, the dog had a progressive engorgement of the upper eyelid of the right eye, whereas during the past few months strabismus and exophthalmos were also noticed. A smaller but yet significant enlargement on the lower eyelid of the left eye, was also noticed. The dog had been treated during the past two years several times by private practitioners with topical antibiotics such as tobramycin and fucidic acid, as well as with systemic antibiotics: amoxycillin and clavulanic acid, along with corticosteroids, without any significant improvement.

Upon thorough ophthalmic examination, strabismus and periorbital swelling in the lateral canthus of the right eye, accompanied by mild exophthalmos and lagophthalmos were recorded. Also, mucopurulent discharge, conjunctival and scleral congestion, epiphora, deep ulcerative keratitis along with corneal oedema and neovascularization were noticed. Furthermore, intense chemosis, epiphora and a small pinkish mass arising from the palpebral conjunctiva of the lower eyelid of the left eye was seen. The globe and rest of the ophthalmic structures appeared normal (Fig. 1). On general physical examination nothing abnormal was noticed.

Neoplasia of both eyelids was strongly suspected and, for definite diagnosis, a series of diagnostic tests were

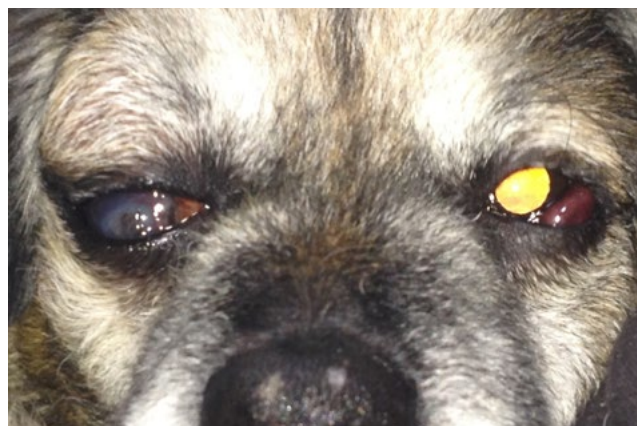

Fig 1: A dog with periorbital swelling and strabismus of the right eye, and oedema of the lower eyelid of the left eye.

performed. More specifically, complete blood count and biochemistry profile along with urinalysis were carried out, but were not diagnostic. Aside a mild neutrophilia (9.3K/ μ l, Reference Values: 3.9-8.0K/ μ l) and a slightly elevated mean platelet volume (MVP) 11.7fl (Reference Values 5.4-9.2), the rest of the values were within normal range. An ocular ultrasonography and computer tomography were performed, confirming the presence of a mass in the upper peribulbar space of the right eye. Lastly, abdominal and thoracic radiographs were taken to rule out metastasis in the respective cavities and proved to be none. Fine needle aspiration of the mass for cytologic examination was performed under general anesthesia prior to surgery, but it was not diagnostic as no pathological cells were identified. Orbital exenteration was the treatment of choice for the right eye, since the damage to the eye was far too progressed. The dog was anesthetized using dexmedetomidine (0.009mg/kg b.w., intramuscularly, Dexdomitor, Zoetis) for premedication, propofol (2mg/kg b.w., intravenously, Vetofol, Norbrook) for the induction and isoflurane (Iso-Vet, Piramal Healthcare) for maintenance of anesthesia. A nonsteroidal anti-inflammatory drug (NSAID), meloxicame (Metacam, Boehringer Ingelheim) was administered pre-surgically at a dose of 0.1mg/kg b.w., intravenously. The transpalpebral approach was the surgical procedure of choice, with excision of the globe and the periorbital tissues, with extended removal of the mass originating from the upper eyelid tarsal area (Fig. 2). During the surgery fine needle aspiration samples were obtained from the mass, in order to have an early diagnosis. One month later, surgical removal of the mass located in the palpe-

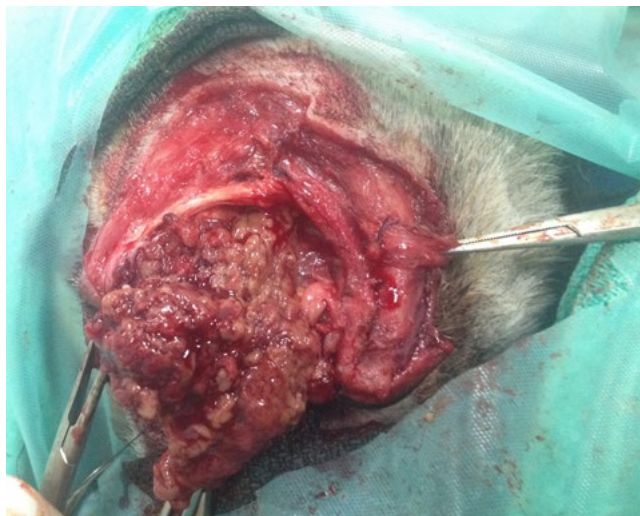

Fig 2: Excision of the globe and periorbital tissues, with extended removal of the tumor of the right eye.

bral conjunctiva of the left lower eyelid was scheduled. The decision to perform the second surgery one month later was based on the age of the dog, the duration and severity of the first surgery, and the time required for the histopathological results of the mass. The dog was anesthetized using acepromazine (0.05mg/kg b.w., intramuscularly, Acepromazine Maleate, VEDCO) and butorfanol (0.1mg/kg b.w., intramuscularly, Butomidor, Richerpharma) for premedication, propofol for the induction and isoflurane for maintenance of anesthesia and meloxicame was given as well (at the doses mentioned before). After incision on the palpebral

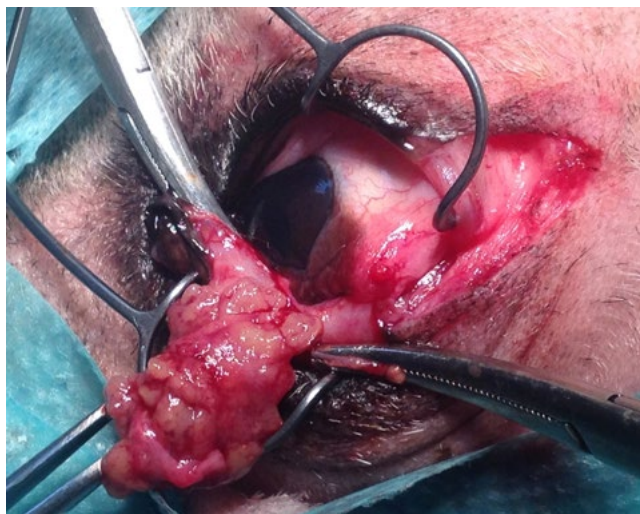

Fig 3: Surgical removal of the mass of the left eye. After incision on the palpebral conjunctiva of the lower eyelid of the left eye, the mass was easily separated from the surrounding tissues and completely excised.

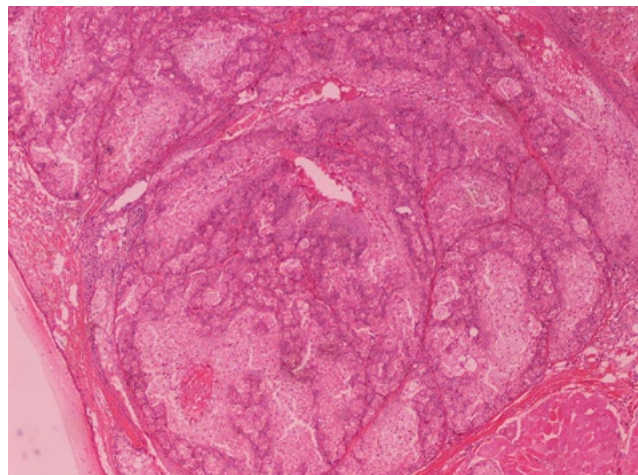


Fig 4: Lobular pattern of the mass, and presence of sheets of undifferentiated basal reserve cells with rare sebaceous differentiation. HE, original magnification $\times 4$.

conjunctiva of the lower eyelid, the mass was easily separated from the surrounding tissues and completely excised (Fig. 3). The right eye globe along with several tissue samples from the mass and periorbital tissues, as well as the mass from the left eye were preserved in 10% formaldehyde and submitted for histopathological examination. Post operatively, after both surgeries, broad spectrum antibiotics; amoxycillin and clavulanic acid (12.5mg/kg b.w., BID for 8 days, per os, Sy-

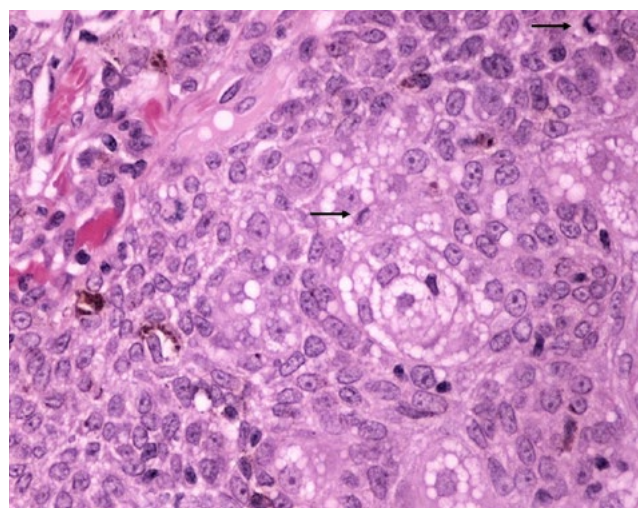


Fig 5: Growth of basaloid cells with scattered aggregates of sebocytes, and melanocytes. Some mitotic figures are seen (arrows) in reserve cells. HE, original magnification $\times 200$.

nulox, Merial) and clindamycin (11mg/kg b.w., SID for 8 days, per os, Antirobe, Sanico n.v.), as well as NSAID meloxicame (0.1mg/kg b.w., SID for 3 days,

Metacam, Boehringer Ingelheim) were administered, and an Elizabethan collar was placed.

Fine needle aspiration samples that were taken during the surgical procedure proved to be inconclusive caused by suboptimal preparation and bloody smears. The histopathological appearance of the examined samples revealed the presence of sheets of undifferentiated basal cells with rare sebaceous differentiation. Focally, scat-

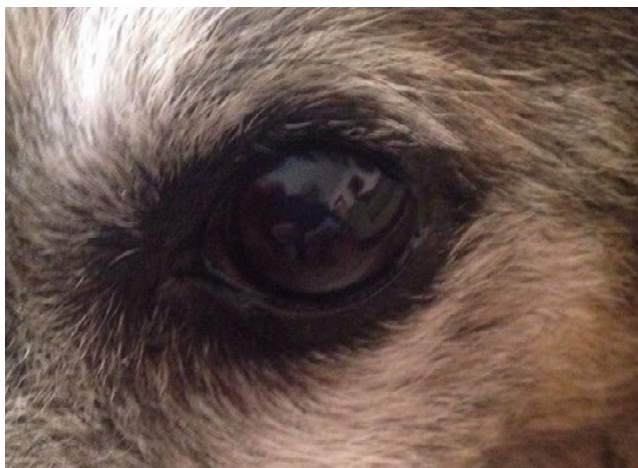

Fig 6: Left eye, 3 months after surgical removal of the mass. The lower eyelid appears normal, without any anatomical deformities.

tered melanocytes were detected. Based on gross and microscopic findings, the present case was diagnosed as bilateral meibomian gland epithelioma (Fig. 4 and 5).

Re-examinations were scheduled a week, one and three months after each surgery and thereafter every six months. The surgical site of the right eye had healed uneventfully and in the left eye no anatomical deformities were noticed in the lower eyelid and the eye looked normal. No relapse was observed in re-examinations within 18 months after the surgery (Fig. 6). Also no metastases were recorded, local or distant, during the follow-up period.

DISCUSSION

Meibomian gland neoplasms can be categorized histologically as adenomas, ductal adenomas, epitheliomas and carcinomas (Goldschmidt and Goldschmidt, 2017). All have a similar clinical appearance as tan, pink, gray, or black masses extending from the meibomian gland orifice and occasionally can erupt the palpebral conjunctiva (Labelle and Labelle, 2013). Meibomian gland adenomas and adenocarcinomas,

according to two retrospective studies, have been reported as the most frequent tumors of the meibomian glands, representing 44%-62% of the canine eyelid tumors in middle-aged or older dogs (Krehbiel and Langham, 1975; Roberts et al., 1986).

Regarding the gross appearance of benign meibomian gland tumors, they present as focal or multifocal nodular masses which are often exophytic and papillary (Dubielzig et al., 2010). Histologically, meibomian gland adenomas have a multilobular arrangement with large vacuolated cells in the center and smaller reserve cells at the periphery of each lobule. Meibomian gland adenocarcinomas appear similar to benign adenomas grossly and microscopically, but adenocarcinomas have a greater percentage of proliferative reserve cells and fewer large foam cells. Also, hemorrhage from hypervascularization and pigmentation from proliferative melanocytes are a common characteristic (Riss et al., 2002). On the other hand, meibomian gland epitheliomas are made up of undifferentiated basal cells with rare sebaceous or squamous differentiation (Dubielzig et al., 2010). Furthermore, in sebaceous epitheliomas mitoses are found only in the reserve cells and do not involve the sebocytes (Goldschmidt and Goldschmidt, 2017). In all benign meibomian gland tumors, a lipogranuloma may be surrounding the tumor (Dubielzig et al., 2010). In the present study, histological examination revealed that both removed masses had sheets of undifferentiated basal cells with rare sebaceous differentiation, focally scattered melanocytes, and mitoses involving the reserve cells, as previously described in the literature.

Until now, objective criteria to differentiate meibomian adenomas and epitheliomas, or the immunohistochemical profile of meibomian gland epitheliomas have not been clearly established (Labelle and Labelle, 2013). According to the literature, epitheliomas should be composed predominantly of basal cells, and some suggest that 90% of the cells must be of the basal type to warrant the diagnosis of epithelioma (Gross et al., 2005). Despite the fact that numerous mitoses may be observed, other features of malignancy are not found in meibomian epitheliomas, therefore some authors classify epitheliomas as benign meibomian adenomas (Labelle and Labelle, 2013).

In dogs, true meibomian carcinomas do occur but are a rare malignant variant of the meibomian gland

tumor (Dubielzig et al., 2010). They are locally invasive and presented with tumor cells with varying amounts of intracytoplasmic lipid vacuoles, anaplastic cellular features and rare meibomian gland secretory features (Dubielzig et al., 2010; Labelle and Labelle, 2013). The nuclei are large and hyperchromatic, with prominent nucleoli, and show pleomorphism and mitotic activity (Labelle and Labelle, 2013). Squamous cell carcinoma affects the non-pigmented eyelids, and is more often in cats, horses and cattle compared to dogs. The preneoplastic lesion appears as an erythematous, scaly area or slightly raised, progressing to an ulcer covered by fibropurulent exudates (Riss et al., 2002). In cats usually it extends into the haired skin, with a concurrent diffuse conjunctival disease (Dubielzig et al., 2010).

Two cases of unilateral meibomian gland epithelioma have been reported in the veterinary literature (Saber et al. 2012; Choi et al. 2013). Choi et al. (2013) described surgical management of a meibomian gland epithelioma in a thoroughbred horse. Histopathological analysis revealed neoplastic basaloid cells forming irregular cell masses, with mildly pleomorphic and undifferentiated appearances, prominent oval nuclei and scant cytoplasm (Choi et al., 2013). Saber et al. (2012) reported an 8-year old Doberman that was presented with an enlargement of the upper left eyelid. The mass was removed surgically by exenteration of the globe. Histopathologically, the mass was composed of a solid growth of irregular islands and trabeculae of basaloid reserve cells, interspersed with fewer sebocytes. Based on clinical and histopathological findings, meibomian gland epithelioma was diagnosed. In that case report no follow-up was obtainable as the dog died of unrelated causes (Saber et al., 2012). In the present case this is the first documented case of bilateral meibomian gland epithelioma in a dog, with no relapse observed within 18 months.

Early surgical removal of any eyelid tumor is the treatment of choice (Frans and van der Woerd, 2013), with the preservation of the structural and functional integrity of the eyelids being of major consideration. Corneal exposure, irritation, and ulceration may result if the structure and function of the eyelid is altered. Removal is also indicated when eyelid masses are rapidly increasing in size, are ulcerated, or cause corneal irritation (Aquino, 2007). Management of canine

eyelid tumors include surgical excision, laser ablation, cryosurgery or combination of the above (Frans and van der Woerd, 2013). The size and site of the mass, and the involvement of the lid margin will determine the selection of the appropriate surgical technique (Aquino, 2007). Regarding the surgical excision of eyelid masses, if the defect after the excision is less than one-third to one-fourth of the total eyelid length, apposition of the surgical sites can be achieved by sutures. If the lid defect approximates up to one-third of the lid length, a 'relief' lateral canthotomy may decrease the resulting lid tension. The surgical techniques that do not require grafts of adjacent tissues, include the partial-thickness excision, the simple 'V' technique (full-thickness excision), and the four-sided method. In cases that the defect is one-third or more of the length of the eyelid, reconstructive blepharoplastic procedures are required that can be modified for each patient. Some of these techniques include the sliding skin flap, sliding 'Z' skin flap, semicircular skin graft, pedicle skin graft, tarsoconjunctival graft, palpebral conjunctival graft (sliding and free), buccal mucosa grafts, rhomboid grafts, and the 'bucket handle' (Cutler-Beard) procedure (Gelatt and Whitley, 2011).

Meibomian tumors are managed by excision, cryosurgery, or a combination of both (Holmberg, 1980). Recurrence rates between dogs treated with cryosurgery and those treated surgically were not significantly different (15.1% and 10.5%, respectively). The mean recurrence time after cryosurgery was 7.4 months and 28.3 months after surgical excision (Holmberg, 1980; Collier and Collins, 1994), whereas the overall cosmetic appearance was better with cryosurgery (Roberts et al., 1986). Cryosurgery may also be considered in cases where anesthetic risk is high, of recurring tumors, and for surgically difficult cases (Holmberg, 1980). In the present case, exenteration of the right eye was the only option, due to the progression of the tumor to the peribulbar space. Surgical excision was preferred for the mass of the left eye due to the location of the tumor, and the lack of invasion to the periorbital tissues and the globe. The cosmetic appearance for both surgeries was acceptable and no relapse was noticed during the follow-up period.

This report shows that despite the fact that meibomian gland epithelioma is rarely encountered, in relation to meibomian gland adenoma; it should be included in

the differential diagnosis of eyelid tumors. Adenomas and epitheliomas of meibomian glands represent 10% of tumor submissions to Comparative Ocular Pathology Laboratory of Wisconsin. The frequency of both adenomas and epitheliomas of the meibomian glands is thought to be under-estimated since small masses are not usually submitted for histological analysis when excised or treated in such a way that the tis-

sue is destroyed (Dubielzig et al., 2010). Prompt surgical intervention and extended excision is the treatment of choice, even though these tumors show low malignancy. Preservation of the eye globe and vision can be attained in most of the cases.

CONFLICT OF INTEREST

The authors have no conflict of interest to declare for this manuscript. ■

REFERENCES

- Aquino SM (2007) Management of eyelid neoplasms in the dog and cat. *Clin Tech Small Anim Pract* 22(2):46–54.
- Choi S-K, Park J-K, Jeon WB, Lee K-H, Cho G-J (2013) Meibomian epithelioma of the lower eyelid in a thoroughbred horse. *Pak Vet J* 33(2):244–247.
- Collier LL, Collins BK (1994) Excision and cryosurgical ablation of severe periocular papillomatosis in a dog. *J Am Vet Med Assoc* 204(6):881–885.
- Dubielzig RR, Ketrung K, McLellan JG, Albert MD (2010) Diseases of the eyelids and conjunctiva. In: *Veterinary Ocular Pathology*. Saunders Elsevier: pp 143–199.
- Frans SC, van der Woerd A (2013) Diseases and Surgery of the Canine Eyelid. In: (eds: Gelatt KN) *Veterinary Ophthalmology*. 5th ed, Wiley-Blackwell, Iowa: pp 832–893.
- Gelatt KN, Whitley DR (2011) Surgery of the eyelids. In: (eds: Gelatt KN, Gelatt JP) *Veterinary Ophthalmic Surgery*. Elsevier Saunders: pp. 89–140.
- Goldschmidt MH, Goldschmidt KH (2017) Epithelial and Melanocytic Tumors of the Skin. In: (eds: Meuten JD) *Tumors in Domestic Animals*. 5th ed, Wiley-Blackwell, Iowa: pp. 88–141.
- Gross TL, Ihrke PJ, Walder EJ, Affolter VK (2005) *Skin Diseases of the Dog and Cat: Clinical and Histopathologic Diagnosis*. 2nd ed, Blackwell Science, Oxford: pp 559–893.
- Holmberg DL (1980) Cryosurgical treatment of canine eyelid tumors. *Vet Clin North Am Small Anim Pract* 10(4):831–836.
- Krehbiel JD, Langham RF (1975) Eyelid neoplasms of dogs. *Am J Vet Res* 36(1):115–119.
- Labelle AL, Labelle P (2013) Canine ocular neoplasia: a review. *Vet Ophthalmol* 16(Suppl1):3–14.
- Maggs DJ (2007) Eyelid. In: (eds: Maggs DJ, Miller PE, Ofri R) *Slatter's Fundamentals of Veterinary Ophthalmology*. 4th ed, Saunders Elsevier, St. Louis, Missouri: pp 107–174.
- Riss RC, Vitali CM, Simons KB (2002) Eyelid tumors. In: (eds: Peiffer RLJ, Simons KB) *Ocular tumors in animals and humans*. Iowa State Press, Iowa: pp 25–86.
- Roberts SM, Severin GA, Lavach JD (1986) Prevalence and treatment of palpebral neoplasms in the dog: 200 cases (1975–1983). *J Am Vet Med Assoc* 189(10):1355–1359.
- Saberi M, Khierandish R, Azari O (2012) Meibomian epithelioma in dog: a case report. *Comp Clin Path* 21(2):227–229.