

Journal of the Hellenic Veterinary Medical Society

Vol 70, No 2 (2019)



Methylsulfonylmethane alone or in combination with thiocolchicoside modulate autoimmune disease in rats with adjuvant arthritis

L. AKRAMAS, L. LEONAVIČIENĖ, R. BRADŪNAITĖ, D. VAITKIENĖ, V. VASILIAUSKAS, I. DUMALAKIENĖ, D. ZABULYTĖ, T. NORMANTIENĖ, I. JONAUSKIENĖ

doi: [10.12681/jhvms.20862](https://doi.org/10.12681/jhvms.20862)

Copyright © 2019, L. AKRAMAS, L. LEONAVIČIENĖ, R. BRADŪNAITĖ, D. VAITKIENĖ, V. VASILIAUSKAS, I. DUMALAKIENĖ, D. ZABULYTĖ, T. NORMANTIENĖ, I. JONAUSKIENĖ



This work is licensed under a [Creative Commons Attribution-NonCommercial 4.0](https://creativecommons.org/licenses/by-nc/4.0/).

To cite this article:

AKRAMAS, L., LEONAVIČIENĖ, L., BRADŪNAITĖ, R., VAITKIENĖ, D., VASILIAUSKAS, V., DUMALAKIENĖ, I., ZABULYTĖ, D., NORMANTIENĖ, T., & JONAUSKIENĖ, I. (2019). Methylsulfonylmethane alone or in combination with thiocolchicoside modulate autoimmune disease in rats with adjuvant arthritis. *Journal of the Hellenic Veterinary Medical Society*, 70(2), 1561–1572. <https://doi.org/10.12681/jhvms.20862>

Methylsulfonylmethane alone or in combination with thiocolchicoside modulate autoimmune disease in rats with adjuvant arthritis

**L. Akramas¹, L. Leonavičienė², R. Bradūnaitė², D. Vaitkienė³, V. Vasiliauskas²,
I. Dumalakienė², D. Zabulytė², T. Normantienė², I. Jonauskienė²**

¹ *Pharmaceutical Company "Aksada", Kaunas, Lithuania*

² *State Research Institute Centre for Innovative Medicine, Vilnius, Lithuania*

³ *National Centre of Pathology, Vilnius, Lithuania*

ABSTRACT. Many active anti-arthritic natural substances are revealed into the past years. The aim of study was to assess the combined efficacy of methylsulfonylmethane (MSM) with thiocolchicoside (Th) (compound MTh) and MSM alone against adjuvant-induced arthritis (AA) in rats. In the first experiment 30 rats and in the second - 21 rats were randomly divided into 6 groups: I gr. - AA + MSM (77 mg/kg), II and V gr. - AA + diclofenac (DF), III and VI gr. - the control AA groups without treatment, IV gr. - MTh (38 mg/kg). DF (1 mg/kg) in both experiments was used as a reference drug. 6 rats were as the healthy control group. AA rats were treated from day 0 to 17. All preparations were suspended in 0.5 ml of 1% starch gel and injected orally 5 days a week. Body weight and joint swelling were monitored 3 times a week. Development of polyarthritis, blood indices, pro-/antioxidant activity and pro-inflammatory cytokines in blood serum, and histopathology of the liver and paw were assessed at the end of experiment. MSM significantly decreased joint swelling on days 3 and 13. MTh in twice lower dose more markedly suppressed joint swelling and also significantly reduced the changes in soft periarticular tissues, synovium and cartilage as compared to the control AA group. Both preparations alleviated infiltration with inflammatory cells and synovial proliferation, as well as protected cartilage destruction and decreased pannus formation. MSM and MTh improved the blood indices and insignificantly suppressed IL-17. They markedly decreased the level of malondialdehyde (MDA). Some anti-oxidant activity of preparations was also confirmed. No toxic effects on the liver were revealed. MSM and MTh attenuated the development of AA in rats. Combination therapy was more effective than single MSM and required the twice lower doses to receive the beneficial anti-arthritic effect. Both preparations could be the potential preventive or therapeutic candidates for the treatment of autoimmune processes in combination with other drugs.

Keywords: methylsulfonylmethane, thiocolchicoside, adjuvant arthritis, rat

Corresponding Author:

L. Leonavičienė, State Research Institute Centre for Innovative Medicine,
Santariškių str. 5, LT-08406 Vilnius, Lithuania.
E-mail address: laima.leonaviciene@imcentras.lt

Date of initial submission:
Date of revised submission:
Date of acceptance:

INTRODUCTION

Rheumatoid arthritis (RA) is a chronic systemic autoimmune inflammatory disorder characterized by severe pain, inflammation of synovial joints with neovascularization, pannus formation and destruction of cartilage. Activated rheumatoid synovial fibroblasts (RASFs) actively participate in RA synovitis (Huber et al., 2006) and aggressively proliferate to form a pannus, which produce inflammatory mediators (Han et al., 2003). Defective apoptosis of RASFs is an important mechanism contributing to synovial hyperplasia in RA (Pattacini et al., 2010; Xiao et al., 2012).

The conventional drug treatment of RA consists from analgesic, non-steroidal anti-inflammatory drugs (NSAIDs), disease-modifying anti-rheumatic drugs (DMARDs), corticosteroids to biologics. However, a common effect of long-term therapy is the development of resistance to treatment and an increased occurrence of adverse effects. In the past several years, there has been a vast increase in a number of complementary drugs purported to have joint-protecting and the antioxidant and free radicals scavenging properties (Kripa et al., 2011; Lopez, 2012; Ezaki et al., 2013), because many studies have validated a role of oxidative stress in RA (Filipin et al., 2008; Kundu et al., 2012; Stamp et al., 2012; Biniecka et al., 2011).

Agents that we investigated are methylsulfonylmethane (MSM) and MSM in combination with Thiocolchicoside (Th) (compound with code name MTh).

MSM is a non-toxic, natural compound widely used as a dietary supplement for its beneficial effects against various diseases, especially arthritis to reduce arthritic and rheumatic pain (Kim et al., 2006; Ameye and Chee, 2006) and (often in combination with glucosamine and chondroitin) to treat or prevent osteoarthritis (Gregory et al., 2008). Previous studies demonstrated that MSM possessed antioxidant and anti-inflammatory properties (Kim et al., 2009; Maranon et al., 2008; Nakhostin-Roohi et al., 2011; Amirshahrokhi et al., 2013) by increasing antioxidant enzyme levels and reducing malondialdehyde (MDA), myeloperoxidase (MPO) and TNF- α (Amirshahrokhi et al., 2013). Its administration protects the development of type II collagen-induced arthritis in mice by modifying the immune responses (Hasegawa et al., 2004). MSM also shows anti-apoptotic effects because dysregulation of apoptosis has been linked with various complications such as autoimmune, inflammatory and other diseases (Karabay et al., 2014).

Thiocolchicoside (Th) is a semi-synthetic sulfur derivative of colchicoside, a naturally occurring glucoside derived from the plant *Gloriosa superba* (Umarmar et al., 2011). It has been used clinically as a muscle relaxant, anti-inflammatory, and analgesic drug (Umarmar et al., 2011; Soonawalla and Joshi, 2008; Kumar et al., 2014; Lahoti, 2012) for the treatment of orthopedic, traumatic and rheumatological disorders (Sandouk et al., 1994). Th significantly suppressed enhanced osteoclastogenesis (Reuter et al., 2012), which is an important pathological feature in many age-associated bone diseases including RA and osteoarthritis (Phan et al., 2004; Reuter et al., 2012). The phytoconstituents that present in the *Gloriosa superba* show analgesic, anti-inflammatory and wound healing action in rats (John et al., 2010; Joshi et al., 2010). Colchicine, an analog of colchicoside, is also a commonly used drug, especially for rheumatic diseases (Efe et al., 2011).

We investigated the effects of MSM and MTh, because to our knowledge, there is no evidence to confirm this issue in detail by using the combination of MSM and Th (compound MTh) by using adjuvant-induced arthritis (AA) in rats which is an experimental model of RA and widely used for testing and developing anti-arthritic and anti-inflammatory agents. Treatment with diclofenac (DF), a standard prescription drug used to treat RA, was used as reference for purposes of comparison.

MATERIALS AND METHODS

Reagents

Complete Freund's adjuvant (CFA), 10% formalin, spirit-formol, hematoxylin, eosin, picrofuxin, toluidine blue, methyl-green-pyronin-y, acetic acid, trichloroacetic acid, orthophosphoric acid, thiobarbituric acid, nitric acid, ferrous sulfate, ascorbic acid, ammonium molybdate, hydrogen peroxide were purchased from Sigma-Aldrich Chemie and Fluca Chemie GmbH (Germany), ketamidol from Richer Pharma AG (Wels, Austria), sedaxylan from Eurovet Animal Health B.V (Holland), and diclofenac (DF) - from Glaxo Wellcome. The enzyme-linked immunosorbent assay (ELISA) kits for determination of IL-6 and IL-17 were produced by Abcam®.

Animals

57 adult male albino rats of 9-10 weeks old, weighing between 180 and 200 g were obtained from the breeding unit of the Department of Biomodels

of the State Research Institute Centre for Innovative Medicine, and used in two experiments of the present study. The animals were divided into 6 experimental groups ($n = 7-10$ per group) and one healthy animal group ($n = 6$), housed in plastic cages and maintained in a temperature-controlled ($22 \pm 2^\circ\text{C}$) environment with a relative humidity of 60% and a 12-h light/dark cycle. The rats were allowed one week to adapt to their environment before initiation of the experiments. They were given standard commercial rodent pellets and water was freely available for the duration of the study. Animal care and handling throughout the experimental procedures in this study was in accordance with the Directive 2010/63/EU of the European Parliament and of the Council of 22 September 2010 on the protection of animals used for scientific purposes. All experimental protocols in this study were approved by the Lithuanian Laboratory Animal Use Ethical Committee for Animal Experiments under the State Food and Veterinary Service.

Induction, treatment and assessment of adjuvant arthritis

Adjuvant arthritis (AA) was induced in 51 rats by a single intra-dermal injection of complete Freund's adjuvant (CFA 0.1 ml) into the foot pad of left hind paw (Murunikara et al., 2014).

Concentrations of compounds and DF sufficient to provide anti-inflammatory effects were selected based upon values reported in the literature and our preliminary studies. In the first experiment 30 rats with AA were divided into 3 groups (10 animals per group), as follows: Group I - Rats received MSM (77 mg/kg), Group II - Rats received DF (1 mg/kg), Group III - Rats without treatment served as the control group. In the second experiment 21 animal was divided into 3 groups (7 rats per group): Group IV - Rats received MTh (38 mg/kg; Th dose in this preparation - 0.25 mg/kg), Group V - DF (1 mg/kg), Group VI - Rats without treatment served as the control group. AA rats in both experiments were medicated from day 0 to 17. All preparations were suspended in 0.5 ml of 1% starch gel and injected orally 5 days a week. Rats of the control groups received the same volume of the starch gel. Six healthy animals (Group VII) served as healthy control. Body weight and joint swelling were monitored three times a week. The anti-arthritic effect of MSM, MTh or DF was evaluated by measuring the paw volume plethysmometrically by using plethysmometer (PVP 1001; Kent Scientific Corporation). The inhibition percentage of investigated indices was calculated for each

animal group in comparison with the control AA group. Duration of experiment was 17 days.

At the end of experimental period all animals were killed by decapitation and then blood was collected for the examination of ESR and leukocytes by using blood analyzer Picoscale (Hungary). Blood serum was collected from each animal to isolate serum. The blood was centrifuged at 3000g for 10 min. and serum drawn and stored at -20°C . The internal organs were removed and weighted. The liver and the injected paws were used for the histopathological examination.

Histopathological examination

The liver and injected paws from AA and healthy rats were excised followed by routine fixation, decalcification, and paraffin embedding. Paraffin bees wax tissue blocks were prepared for sectioning at 5 micron thickness by sledge microtome. The obtained tissue sections were collected on glass slides, deparaffinized and stained with hematoxylin-eosin, picrofuxin, toluidine blue, methyl-green-pyronin-y and safranin O for histopathological examination through the light microscope. Histological assessment of changes in the liver, soft periarticular tissues, synovium and cartilage was performed. During the processing and analysis of the liver and joints, the pathologist was "blinded" to the animal groups and the drug treatments. Each parameter was scored on a 0 to 3 point scale, where 0 means the absence of changes, 0.5 - traces of changes, 1 - minimal changes, 2 - moderate changes, 3 - heavy changes.

Determination of lipid peroxide level and catalase (CAT) activity in blood serum

Lipid peroxidation assessed as malondialdehyde (MDA) levels in the blood serum, expressed as nmol/ml, were determined by the thiobarbituric acid reaction at 532 nm spectrophotometrically by the method of Gavrillov and co-workers (1987). Catalase (CAT) activity, expressed in nmol/L/min, was measured at 410 nm as described by Koroliuk and co-authors (1988).

Measurement of cytokines levels

Cytokines like IL-6 and IL-17 were measured in the serum of the control and experimental animals by using respective enzyme-linked immunosorbent assay (ELISA) kits specific for rats (ab119536-IL-17 Rat ELISA Kit and ab119548-IL-6 Rat ELISA Kit) according to procedure recommended by manufacturer's instructions (abcam®; UK). Each sample was assayed in duplicate. The concentrations of cytokines were determined with the help of a standard curve.

Statistical analysis

Statistical analysis was done by one-way analysis of variance ANOVA using PRISM Software (Graph-Pad Software, San Diego, CA, USA) and Student's t-test. The nonparametric Mann-Whitney U test was used to evaluate the histological changes. All data were expressed as the mean \pm SEM and considered to be statistically significant at P values smaller than or equal to 0.05.

RESULTS

Effect of MSM and MTh on the body and organ's weight

The initial body weight of rats did not differ among the groups and slightly increased during the experiment in all investigated groups although no significant differences between the groups were observed (data not shown).

Significant increase of the liver, kidney and spleen weight and decrease of the thymus weight were observed in rats with AA compared with the healthy animals (Table 1).

In the first experiment rats treated with MSM (group I) or DF (group II) showed only a significant decrease of the relative kidney weight (MSM - $P < 0.05$; DF - $P < 0.001$) in comparison with the animals of the control group III. The relative weights of the liver were the same as in the healthy rats, but the spleen weight was significantly higher and the thymus weight was lower in both treated groups than those in the group of healthy animals.

In the second experiment rats treated with MTh (group IV) showed a significantly lower the relative

weight of the liver ($P < 0.02$) and markedly higher weight of the thymus ($P < 0.01$) than those in the control VI group. The same effect was found after the treatment of AA with DF (liver - $P < 0.01$; thymus - $P < 0.001$).

Histopathological changes in the liver

There was no histopathological alteration and the normal histological structure of hepatic parenchyma was recorded in the liver sections of healthy animals (data not shown).

The effect of MSM on the liver of rats with AA was similar to the effect of diclofenac (Table 2). Both preparations MSM and DF significantly decreased inflammatory infiltration of hepatic stroma with lymphocytes by 50.6% ($P < 0.01$) and 56.8% ($P < 0.01$) and the general inflammatory reaction by 38.7% ($P < 0.05$) and 48.1% ($P < 0.05$) respectively in comparison with the control AA group. Preparation MTh, diminished alteration of parenchyma by 28.8% ($P < 0.02$), infiltration of hepatic stroma with lymphocytes by 80.9% ($P < 0.02$), macrophages by 79% ($P < 0.05$) and general inflammatory reaction by 64.2% ($P < 0.05$). The penetration of inflammatory cells into the lobule decreased by 88.3% compared to the control AA group ($P < 0.05$). The effect of MTh on the liver was similar to the effect of DF except infiltration with macrophages, where this preparation didn't show the significant decrease. So, after the treatment with MSM and MTh no toxic effects on the liver were observed, and they improved histopathological changes in this organ caused by AA. It should be noted that the effect of MTh was more significant than that of MSM although it was used in twice lower dose.

Table 1. Effect of MSM and MTh on relative organ's weight

Experiment	Groups	Liver (g/kg ⁻¹)	Kidney (g/kg ⁻¹)	Spleen (g/kg ⁻¹)	Thymus (g/kg ⁻¹)
First	IAA + MSM	3.24 \pm 0.11	0.88 \pm 0.03 *	+ 0.45 \pm 0.03	+ 0.124 \pm 0.010
	II AA + DF	2.95 \pm 0.07 *	0.86 \pm 0.02 *	+ 0.40 \pm 0.01 *	0.166 \pm 0.016 *
	III AA control	+ 3.46 \pm 0.13	+ 0.96 \pm 0.02	+ 0.51 \pm 0.03	+ 0.110 \pm 0.010
	IV AA + MTh	3.45 \pm 0.22 *	+ 0.91 \pm 0.02	+ 0.64 \pm 0.07	+ 0.120 \pm 0.009 *
Second	V AA + DF	+ 3.50 \pm 0.13 *	0.88 \pm 0.02	+ 0.58 \pm 0.05	+ 0.130 \pm 0.009 *
	VIAA control	+ 4.39 \pm 0.24	+ 1.00 \pm 0.05	+ 0.88 \pm 0.10	+ 0.080 \pm 0.008
Healthy rats		3.05 \pm 0.10	0.84 \pm 0.02	0.25 \pm 0.01	0.170 \pm 0.016

Note: Adjuvant arthritis (AA) was induced by a single injection of 0.1 ml of complete Freund's adjuvant (CFA) into the left hind paw. I group was treated prophylactically (since AA inducing day) with 77 mg/kg of methylsulfonylmethane (MSM) and IV group with 38 mg/kg of MTh (MSM and thiocolchicoside (Th) complex). II and V groups in both experiments were treated with 1 mg/kg of diclofenac (DF). Preparations were suspended in the 1% starch gel and injected orally 5 times a week in a volume of 0.5 ml. Controls AA groups (III and VI gr.) received the same volume of the starch gel. * The differences are significant in comparison with the control group. + The differences are significant in comparison with the healthy animal's group.

Table 2. Effects of MSM and MTh on the liver in AA rats

Index	Groups						
	First experiment			Second experiment			
	I AA+MSM	II AA+DF	III AA control	IV AA+MTh	V AA+DF	VI AA control	
Alteration of parenchyma	0.75±0.08	0.65±0.11	0.88±0.15	1.21±0.10 *	0.71±0.10 *	1.70±0.12	
Hypervolemia of <i>V. centralis</i>	0.55±0.09	0.60±0.10	0.63±0.16	1.36±0.21	0.79±0.15	0.80±0.30	
Inflammatory infiltration of hepatic stroma	Lymphocytes	0.40±0.10 *	0.35±0.11 *	0.81±0.09	0.21±0.10 *	0.14±0.09 *	1.10±0.29
	Granulocytes	0.10±0.06	0	0.13±0.08	0.21±0.15	0	0.30±0.20
	Macrophages	0.90±0.12	0.70±0.18	0.88±0.16	0.21±0.15 *	0.29±0.15	1.00±0.31
	General	0.65±0.13 *	0.55±0.17 *	1.06±0.11	0.43±0.17 *	0.29±0.15 *	1.20±0.30
Penetration into the lobule	0.75±0.13	0.45±0.20	0.56±0.17	0.14±0.14 *	0.14±0.14 *	1.20±0.37	

Note: Adjuvant arthritis (AA) was induced by a single injection of 0.1 ml complete Freund's adjuvant (CFA) into the left hind paw. I group (n = 10) was treated prophylactically (since AA inducing day) with 77 mg/kg of methylsulfonylmethane (MSM) and IV group (n = 7) with 38 mg/kg of MTh ((MSM and thiocolchicoside (Th) complex). II (n = 10) and V (n = 7) groups in both experiments were treated with 1 mg/kg of diclofenac (DF). Preparations were suspended into the starch gel and injected orally 5 times a week in a volume of 0.5 ml. Controls AA groups (III and VI gr.) received the same volume of the starch gel. Duration of experiment is 17 days. Hepatic tissue was fixed in spirit-formol (1:9), embedded in paraffin, and 5 µm-thick histological sections of the tissue were stained with haematoxylin-eosin (for visualization of inflammation and inflammatory cell infiltration and necrosis of hepatocytes). The histological assessment of changes in the liver was performed in a blinded manner by pathologist. Each parameter was scored on a 0 to 3 point scale, where 0 means the absence of changes, 0.5 - traces of changes, 1 - minimal changes, 2 - moderate changes, 3 - heavy changes. * The differences are significant in comparison with the control group.

Hematological parameters

There was a significant increase in ESR and leukocyte's count of arthritic rats in both experiments when compared with the healthy rats (Fig. 1A). MSM and MTh significantly reduced ESR by 48.7% (P < 0.01) and 41.2% (P < 0.001), and leukocyte's count by 41.2% (P < 0.001) and 24.6% (P < 0.02) respectively compared with due control groups.

Effect of MSM and MTh on AA induced alterations in lipid peroxidation and antioxidant enzyme CAT activity

AA (Groups III and VI) induced serum lipid peroxidation reflected by a significant increase in MDA level compared with the healthy control (Fig. 1B). This was also accompanied by a significant 39.9% decrease in CAT activity in the first experiment and by 44.7% in the second experiment. Treatment with MSM (Group II) caused a significant 44.8% (P < 0.0001) reduction in MDA level as a 20.3% elevation in CAT activity compared to the control AA group III. It should be noted that the effect of MSM and DF on MDA and CAT activity was similar.

Although the administration of MTh for the treatment of AA (Group IV) didn't induce a significant change in CAT activity (it insignificantly increased

by 27.2% and the differences between the treated and the control group was near to significant - t = 1.86), it markedly (P < 0.001) decreased MDA level in the blood serum by 58% in comparison with the control AA group VI.

Effect of MSM and MTh on pro-inflammatory cytokines in blood serum of rats with AA

The cytokines in the serum were detected on day 17 after immunization with CFA. We couldn't to detect IL-6 in the blood serum of healthy, tested and the control animals. MSM and MTh suppressed IL-17 level by 22.58% and 27.9% respectively but they didn't induce the significant changes compared to the control AA groups (Fig. 1C).

Effect of AA treatment with MSM and MTh on the joint swelling

Effect of both preparations on joint swelling was not more effective than DF (Fig. 2). MSM significantly decreased joint swelling only on days 3 (P < 0.001) and 13 (P < 0.05), and at the end of experiment this suppression reached 19.6% in comparison with the control group III (Fig. 2A). MTh suppressed joint swelling till day 10 (P < 0.05-0.002) and on day 15 (P < 0.02) (Fig. 2B). So, preparation MTh was significantly active on all the days in the acute phase of AA.

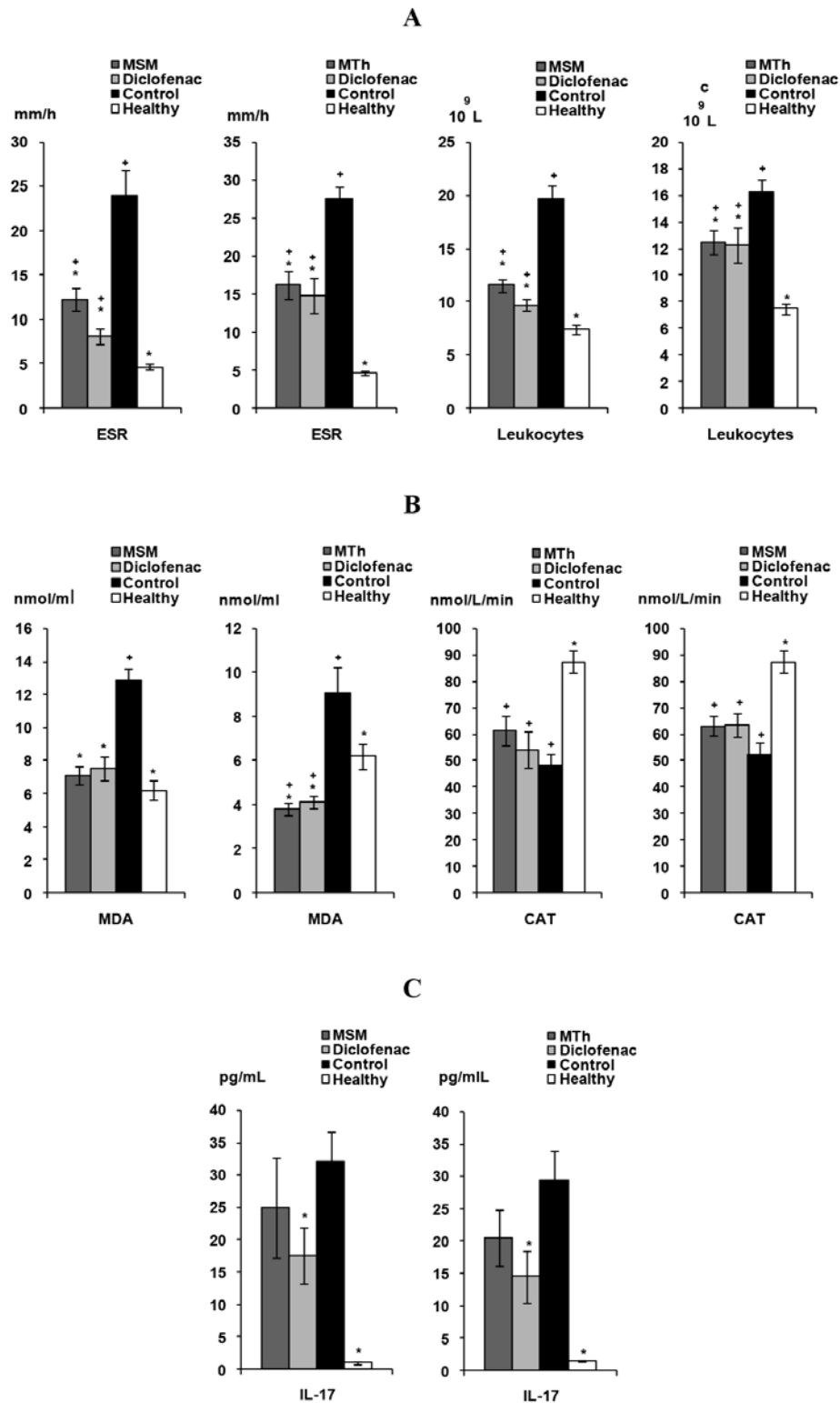


Figure 1. Blood indices (A), pro-/antioxidant activities (B) and level of interleukin-17 (C) in rats with adjuvant arthritis treated with preparations MSM and MTh.

Adjuvant arthritis (AA) was induced by a single injection of 0.1 ml complete Freund's adjuvant (CFA) into the left hind paw. I group (n = 10) was treated prophylactically (since AA inducing day) with 77 mg/kg of methylsulfonylmethane (MSM) and IV group (n=7) with 38 mg/kg of MTh ((MSM and thiocolchicoside (Th) complex). II (n = 10) and V (n = 7) groups in both experiments were treated with 1 mg/kg of diclofenac (DF). Preparations were suspended into the starch gel and injected orally 5 times a week in a volume of 0.5 ml. Controls AA groups (III and VI gr.) received the same volume of the starch gel. * Differences are statistically significant in comparison with the control group. + Differences are statistically significant in comparison with healthy rats.

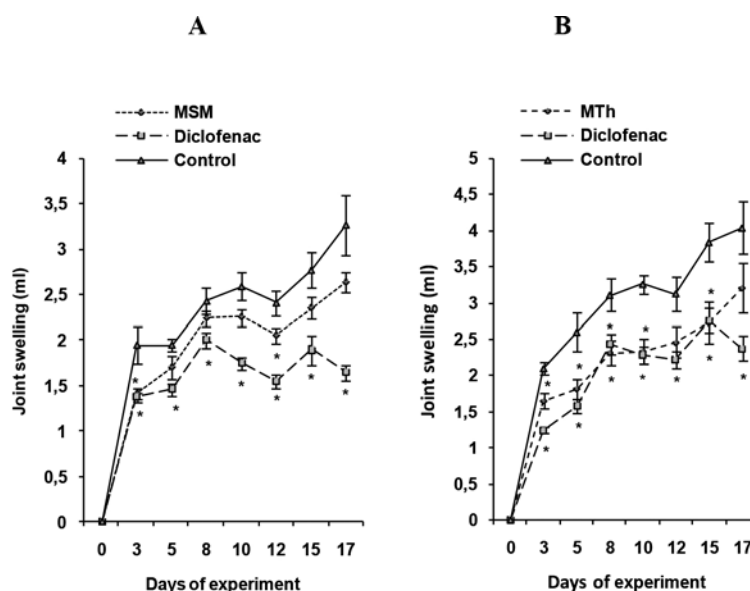


Figure 2. Joint swelling of rats with adjuvant arthritis treated with preparations MSM (A) and MTh (B).

Adjuvant arthritis (AA) was induced by a single injection of 0.1 ml complete Freund's adjuvant (CFA) into the left hind paw. I group (n = 10) was treated prophylactically (since AA inducing day) with 77 mg/kg of methylsulfonylmethane (MSM) and IV group (n = 7) with 38 mg/kg of MTh ((MSM and thiocolchicoside (Th) complex). II (n = 10) and V (n = 7) groups in both experiments were treated with 1 mg/kg of diclofenac (DF). Preparations were suspended into the starch gel and injected orally 5 times a week in a volume of 0.5 ml. Controls AA groups (III and VI gr.) received the same volume of the starch gel. * Differences are statistically significant in comparison with the control group.

Effect of MSM and MTh treatment on histological findings in the joints

There were no abnormalities in the joints of healthy rats (data not shown). CFA administered control groups showed thinning of cartilage, erosions, pannus formation, extensive infiltration of inflammatory cells in the soft periarticular tissues and synovium.

MSM and MTh decreased inflammatory infiltration in the soft periarticular tissues (Table 3). Significantly lower infiltration with macrophages ($P < 0.02$) was observed after the treatment with MSM and leukocytes ($P < 0.0001$) - with MTh. Both preparations decreased general inflammatory reaction: MSM by 36.6% ($P < 0.001$) and MTh by 21.3% ($P < 0.0001$) compared with the control arthritic groups. Suppression of edema and angiomas was also observed, although this suppression was some lower than by using diclofenac. MSM markedly suppressed edema and angiomas by 49% ($P < 0.001$) and 46.6% ($P < 0.002$) and MTh by 33% ($P < 0.001$) and 31% ($P < 0.01$) respectively in comparison with the control AA groups.

The highest pathological changes in the synovium were found in the control AA groups. Both investigated preparations MSM and MTh significantly sup-

pressed synovium villy proliferation. Proliferation decreased by 38.6% in MSM group ($P < 0.001$) and by 29.6% in MTh group ($P < 0.02$). Significant differences among the treated and the control AA groups were observed after evaluation of synovium edema, where marked decrease of it by 42.7% vs control was found in the group that received MSM ($P < 0.05$) and by 46.5% ($P < 0.001$) in the group treated with MTh. Preparation MSM significantly decreased synovium inflammatory infiltration with macrophages by 73.3% and it was the same as the action of DF ($P < 0.001$), and preparation MTh - infiltration with leukocytes by 51.9% ($P < 0.05$). General inflammatory reaction in synovium was lower by 37.5% ($P < 0.02$) than in the control AA group after the treatment with MSM and by 35.6% ($P < 0.01$) in animals treated with MTh. Differently than MSM, preparation MTh significantly diminished angiomas in synovium tissue by 48.5% ($P < 0.01$).

Table 3. Histopathological changes in the joints after the treatment of AA with MSM and MTh

Tissue	Index	First experiment				Second experiment		
		Groups				Groups		
		I AA+MSM	II AA+DF	III AA control	IV AA+MTh	V AA+DF	VI AA control	
Soft periarticular tissues	Inflammatory infiltration	Lymphocytes	1.05±0.09	0.90±0.19	1.19±0.26	1.14±0.14	0.71±0.10 *	1.50±0.18
		Leukocytes	1.10±0.23	0.60±0.18 *	1.63±0.29	2.36±0.09 *	1.21±0.21 *	3.00±0.00
		Macrophages	0.60±0.10 *	0.90±0.12	1.00±0.09	1.14±0.18	0.86±0.09 *	1.67±0.17
		General	1.35±0.11 *	1.35±0.08 *	2.13±0.08	2.36±0.09 *	1.36±0.09 *	3.00±0.00
	Edema	1.05±0.09 *	0.65±0.11 *	2.06±0.11	1.79±0.10 *	0.71±0.15 *	2.67±0.17	
	Angiomatosis	0.70±0.08 *	0.65±0.08 *	1.31±0.13	1.78±0.15 *	0.57±0.07 *	2.58±0.20	
	Proliferation	1.00±0.10 *	0.80±0.08 *	1.63±0.21	1.64±0.18 *	0.86±0.14 *	2.33±0.17	
Synovium	Inflammatory infiltration	Edema	0.75±0.13 *	0.25±0.11 *	1.31±0.09	1.07±0.20	0.36±0.14 *	2.00±0.00
		Lymphocytes	0.55±0.12	0.35±0.13 *	0.94±0.20	1.14±0.09	0.36±0.09	0.83±0.21
		Leukocytes	0.75±0.13	0.25±0.11 *	1.13±0.23	1.00±0.27 *	0.36±0.21 *	2.08±0.35
		Macrophages	0.20±0.08 *	0.20±0.08 *	0.75±0.09	1.07±0.13	0.50±0.11 *	1.17±0.21
	General	0.90±0.12 *	0.55±0.12 *	1.44±0.15	1.50±0.15 *	0.71±0.15 *	2.33±0.17	
	Angiomatosis	0.75±0.08	0.40±0.10 *	1.25±0.23	1.07±0.20 *	0.57±0.17 *	2.08±0.20	
	Cartilage	Erosium	0.80±0.20 *	0.65±0.15 *	2.00±0.00	2.00±0.00	2.00±0.00	2.00±0.00
Usura		0.30±0.13 *	0.20±0.11 *	1.06±0.27	1.28±0.18	0.21±0.10 *	1.50±0.22	
Fissura		0	0	0	0.64±0.18	0	0.50±0.34	
Pannus		0.35±0.11 *	0.05±0.05 *	1.00±0.27	1.57±0.20 *	0.43±0.23 *	2.33±0.21	
Thinning of cartilage		0.10±0.06	0.05±0.05	0.38±0.16	0.43±0.17 *	0.07±0.07 *	1.33±0.36	

Note: Adjuvant arthritis (AA) was induced by a single injection of 0.1 ml complete Freund's adjuvant (CFA) into the left hind paw. I group (n = 10) was treated prophylactically (since AA inducing day) with 77 mg/kg of methylsulfonylmethane (MSM) and IV group (n = 7) with 38 mg/kg of MTh (MSM and thiocolchicoside (Th) complex). II (n = 10) and V (n = 7) groups in both experiments were treated with 1 mg/kg of diclofenac (DF). Preparations were suspended into the starch gel and injected orally 5 times a week in a volume of 0.5 ml. Controls AA groups (III and VI gr.) received the same volume of the starch gel. * The differences are significant in comparison with the control group.

Alone MSM in dose of 77 mg/kg showed more pronounced effect on cartilage than combined preparation MTh in twice lower dose. There were no fissures in all the tested groups of animals in the first experiment. Erosium ($P < 0.001$) and usures ($P < 0.05$) significantly decreased in MSM group. Both preparations MSM and MTh significantly suppressed pannus formation compared with the control groups: MSM induced 65% suppression ($P < 0.05$) and MTh - 32.6% suppression ($P < 0.05$). Traces of cartilage thinning was observed only in two animals treated with MSM, but no significant changes were observed in comparison with the control AA group. MTh significantly decreased thinning of cartilage by 67.7% ($P < 0.05$), although this effect was lesser than effect of DF.

DISCUSSION

RA is presently one of the most predominant diseases worldwide. However, unfortunately, there has been no specific cure for RA. Because current treatments for arthritis result in unwanted side effects and tend to be expensive, natural products devoid of such disadvantages offer a novel opportunity. Through this study, we have demonstrated that the supplementation of compounds such as MSM and MTh, could play a role in protecting against biochemical, immunological and histological alterations in AA rats. The results of our study suggest that the prophylactic use of MSM and its combination with Th (compound MTh) in twice lower dose may have a significant effect on slowing disease progression although this therapeutic effect was not stronger than the effect of DF. MTh and

to a lesser extent MSM, were found to inhibit joint swelling and the treatment with both preparations was also associated with decreased histological changes in joints. The main pathological changes of RA are that leukocytes infiltrate into articular cavity, cause recurrent synovitis (Cooles and Isaacs, 2011) and that invasive pannus forms to damage cartilage, bone and surrounding tissue. In our study, compound MTh significantly decreased infiltration with leukocytes in the soft periarticular tissues and synovium.

It is known that MSM is one of the most popular dietary supplements, which is expected to relieve inflammation in arthritis. Recently, it has been shown that orally pretreatment of rats with MSM (400 mg/kg) exhibits a hepato-protective effect against carbon tetrachloride induced acute liver injury by suppressing pro-inflammatory cytokine release and apoptotic Bax/Bcl-2 ratio and increasing antioxidant enzyme levels (Kamel and Morsy, 2013). MSM is used as singly or in combination with other nutrients in dietary supplements for OA because sulfur is needed for formation of connective tissue.

In our study we combined MSM with Th (complex MTh). The latter has been used clinically as a muscle relaxant, anti-inflammatory, and analgesic drug (Umalkar et al., 2011; Soonawalla and Joshi, 2008; Kumar et al., 2014; Lahoti, 2012) for the treatment of orthopedic, traumatic and rheumatologic disorders (Sandouk et al., 1994). We indicated a successful anti-arthritis activity of this combined preparation. It is interesting that MTh in twice lower dose than MSM alone exerted inhibitory effect on the development of AA.

No particular behavior, clinical or physiological signs were observed in animals treated with both compounds, suggesting that used preparation's doses are probably not toxic *in vivo*. It was confirmed also by histological examination of the liver, where significantly lower alterations of hepatic parenchyma and stroma were found in the treated groups.

Increase in leukocyte count has been suggested to be one of the characteristic diagnoses of arthritis. In our present study, arthritic animals showed elevated leukocyte level. MSM and MTh significantly decreased leukocytes, revealing their beneficial role against arthritis. ESR which significantly increased in arthritic control groups has been remarkably decreased after the treatment with both preparations and standard drug DF, thus justifying significant role of

preparations in arthritic conditions.

ROS in arthritis is not surprising since oxidative stress or ROS serve as mediators of tissue damage (Jayadevi et al., 2013). Antioxidant enzymes are present in biological systems to protect the tissue from oxidative injury (Sabina and Rasool, 2008). Our results demonstrated that the activity of CAT was decreased in AA animals, which may have been due to increased production of free radicals. The decrease in anti-oxidant enzyme activity correlated with increased lipid peroxidation quantified by measurement of the MDA. It is well known that MDA is a terminal product of lipid peroxidation and so the content of MDA can be used to estimate the extent of lipid peroxidation (Huang et al., 2012; Messarah et al., 2010). Elevated levels of MDA have been reported in the serum, liver and synovial fluid in patients with RA (Sarban et al., 2005). The increased levels of MDA may be due to its release from neutrophils and monocytes during inflammation. It appeared that the antioxidant defense was compromised in the AA and other kinds of arthritis as evidenced by increased MDA concentrations and decreased antioxidant enzyme CAT activity (Huang et al., 2012). In our study biochemical assessments showed attenuated lipid peroxidation and increased CAT activity after the treatment with preparations MSM and MTh as compared to the control AA groups. Taken together, our results prove some antioxidant action of these compounds. May be higher doses of MSM and MTh in our experiments could be used to achieve more pronounced antioxidant activity.

Data on therapeutic effects of MSM and MTh led us to assay the ability of these preparations to prevent AA development in rats. These findings are consistent with those reported by other authors (Huang et al., 2012; Kamel and El Morsy, 2013), who also showed an ability of MSM or Th to reduce inflammation and to enhance antioxidant enzyme activity and induction of direct scavenging of free radicals.

It is known that pro-inflammatory cytokines such as TNF- α , IL-6, IL-17 play an important role in RA. Cytokines observed to be induced in the early phases following exposure to CFA are TNF- α , IL-12, IL-6, IFN- γ and several chemokine's (Billiau and Matthys, 2001). IL-6 is cytokine likely to be induced by CFA that may be relevant to induction of autoimmune diseases. But as state Billiau and Matthys (2001), direct *in vivo* demonstration of IL-6 production following injection of CFA is not available, that also showed our investigations.

Another cytokine IL-17, a major product of T cells, plays the important role as an upstream mediator of RA pathogenesis. It promotes inflammation via enhancing the production of IL-1 β , TNF- α and IL-6 (Zhang et al., 2013; Shi et al., 2015). In our study, concentration of IL-17 significantly increased in the blood serum of rats with AA compared to the healthy control, and its reduction was demonstrated in response to MSM and MTh. Although no significant differences were found in the serum concentrations of IL-17, both preparations had a tendency to reduce this cytokine level compared with the control AA groups.

Data discussed above suggest that the anti-arthritis effect of investigated compounds could occur through the inhibition of oxidative stress in AA and increased antioxidant activity after the treatment.

CONCLUSIONS

This study has demonstrated that the oral administration of MSM or its combination with Th (compound MTh) attenuates the development of AA in

rats. Compounds had an inhibitory effect on joint swelling in AA model induced by CFA injection. This correlated with attenuation of histological changes in injected joints, decreased level of IL-17, together with significantly lower levels of MDA and increased CAT activity. These therapeutic benefits were comparable with those achieved by treating with the clinically available drug, diclofenac. MSM alone and in combination with Th (compound MTh) can be the safe and well tolerated dietary supplements that are two important parameters for the promising drug candidates for joint diseases therapy. These are the first data to indicate successful anti-arthritis activity of combined MTh preparation. Findings provide clues that investigated compounds may be the promising agents for preventing and treating of autoimmune diseases in combination with other drugs.

CONFLICT OF INTEREST

The authors declare that there are no conflicts of interest.

REFERENCES

- Ameje LG, Chee WS (2006) Osteoarthritis and nutrition. From nutraceuticals to functional foods: a systematic review of the scientific evidence. *Arthritis Res Ther* 8:R127.
- Amirshahrokhi K, Bohlooli S (2013) Effect of methylsulfonylmethane on paraquat-induced acute lung and liver injury in mice. *Inflammation* 36:1111-1121.
- Billiau A, Matthys P (2001) Modes of action of Freund's adjuvants in experimental models of autoimmune diseases. *J Leukoc Biol* 70:849-860.
- Biniecka M, Kennedy A, Ng CT, Chang TC, Balogh E, Fox E, Veale DJ, Fearon U, O'Sullivan JN (2011) Successful tumour necrosis factor (TNF) blocking therapy suppresses oxidative stress and hypoxia-induced mitochondrial mutagenesis in inflammatory arthritis. *Arthritis Res Ther* 13:R121.
- Cooles FA, Isaacs JD (2011) Pathophysiology of rheumatoid arthritis. *Curr Opin Rheumatol* 23:233-240.
- Efe C, Purnak T, Ozaslan E, Milanioglu A (2011) Thiocolchicoside-induced liver injury. *Clinics* 66:521-522.
- Ezaki J, Hashimoto M, Hosokawa Y, Ishimi Y (2013) Assessment of safety and efficacy of methylsulfonylmethane on bone and knee joints in osteoarthritis animal model. *J Bone Miner Metab* 31:16-25.
- Filipin LI, Vercelino R, Marroni NP, Xavier RM (2008) Redox signaling and the inflammatory response in rheumatoid arthritis. *Clin Exp Immunol* 152:415-422.
- Gavrilov VB, Gavrilova AR, Mazhul LM (1987) Methods of determining lipid peroxidation products in the serum using a thiobarbituric acid test. *Vop Med Khim* 33:118-122.
- Gregory PJ, Sperry M, Wilson AF (2008) Dietary supplements for osteoarthritis. *Am Fam Physician* 77:177-184.
- Han MK, Kim JS, Park BH, Kim JR, Hwang BY, Lee HY, Song EK, Yoo WH (2003) NF-kappaB-dependent lymphocyte hyperadhesiveness to synovial fibroblasts by hypoxia and reoxygenation: Potential role in rheumatoid arthritis. *J Leukoc Biol* 73:525-529.
- Hasegawa T, Ueno S, Kumamoto S, Yoshikai Y (2004) Suppressive effect of methylsulfonylmethane (MSM) on type II collagen-induced arthritis in DBA/1 J mice. *Jpn Pharmacol Ther* 32:421-427.
- Huang JI, Zhu M, Tao Y, Wang S, Chen J, Sun W, Li S (2012) Therapeutic properties of quercetin on monosodium urate crystal-induced inflammation in rat. *J Pharm Pharmacol* 64:1119-1127.
- Huber LC, Distler O, Tamer I, Gay RE, Gay S, Pap T (2006) Synovial fibroblasts: key players in rheumatoid arthritis. *Rheumatology* 45:669-675.
- Jeyadevi R, Sivasudha T, Rameshkumar A, Ananth DA, Aseervatham GS, Kumaresan K, Kumar LD, Jagadeeswari S, Renganathan R (2013) Enhancement of anti-arthritis effect of quercetin using thioglycolic acid-capped cadmium telluride quantum dots as nanocarrier in adjuvant induced arthritic Wistar rats. *Colloids Surf B Biointerfaces* 112:255-263.
- John JC, Fernandes J, Nandguda T, Niphade SR, Savla A, Deshmukh PT (2010) Analgesic and anti-inflammatory activities of the hydrochloric extract from *G. superba* Linn. *Int J Green Pharma* 3:215-219.
- Joshi CS, Sanmuga Priya E, Mathela CS (2010) Isolation and anti-inflammatory activity of colchicinoids from *Gloriosa superba* seeds. *Pharm Biol* 48:206-209.
- Kamel R, El Morsy EM (2013) Hepatoprotective effect of methylsulfonylmethane against carbon tetrachloride-induced acute liver injury in rats. *Arch Pharm Res* 36:1140-1148.
- Karabay AZ, Aktan F, Sunguroglu A, Buyukbingol Z (2014) Methylsulfonylmethane modulates apoptosis of LPS/IFN-gamma-activated RAW 264.7 macrophage-like cells by targeting p53, Bax, Bcl-2, cytochrome c and PARP proteins. *Immunopharmacol Immunotoxicol* 36:379-389.
- Kim LS, Axelrod LJ, Howard P, Buratovich N, Waters RF (2006) Efficacy of methylsulfonylmethane (MSM) in osteoarthritis pain of the knee: a pilot clinical trial. *Osteoarthritis Cartilage* 14:286-294.
- Kim YH, Kim DH, Lim H, Baek DY, Shin HK, Kim JK (2009) The anti-inflammatory effects of methylsulfonylmethane on lipopolysaccharide-induced inflammatory responses in murine macrophages. *Biol Pharm Bull* 32:651-656.
- Koroliuk MA, Ivanova LI, Maiorova IG, Tokarev VE (1988) A method of determining catalase activity. *Lab Delo* 1:16-19.
- Kripa KG, Chamundeeswari D, Thanka J, Uma Maheswara Reddy C (2011) Modulation of inflammatory markers by the ethanolic extract of *Leucas aspera* in adjuvant arthritis. *J Ethnopharmacol* 134:1024-1027.
- Kumar S, Rani S, Siwach R, Verma P (2014) To compare the efficacy and safety of fixed dose combination of thiocolchicoside and aceclofenac versus chlorzoxazone, aceclofenac and paracetamol in patients with acute lower backache associated with muscle spasm. *Int J Appl Basic Med Res* 4:101-105.
- Kundu S, Ghosh P, Datta S, Ghosh A, Chattopadhyay S, Chatterjee M (2012) Oxidative stress as a potential biomarker for determining disease activity in patients with rheumatoid arthritis. *Free Radic Res* 46:1482-1489.
- Lahoti G (2012) To evaluate efficacy and safety of fixed dose combination of aceclofenac+paracetamol+thiocolchicoside (acenac-MR) in the treatment of acute back pain. *J Indian Med Assoc* 10:56-58.
- Lopez HL (2012) Nutritional interventions to prevent and treat osteoarthritis. Part II: Focus on micronutrients and supportive nutraceuticals. *Am Acad Physical Med Rehabil* 4:155-168.
- Maranon G, Munoz-Escassi B, Manley W, Garcia C, Cayado P, de la Muela MS, Olábarri B, León R, Vara E (2008) The effect of methyl sulphonyl methane supplementation on biomarkers of oxidative stress in sport horses following jumping exercise. *Acta Vet Scand* 50:45.
- Messarah M, Boumendjel A, Chouabia A, Klibet F, Abdennour C, Boulakoud MS, Feki AE (2010) Influence of thyroid dysfunction on liver lipid peroxidation and antioxidant status in experimental rats. *Exp Toxicol Pathol* 62:301-310.
- Murunnikara V, Rasool M (2014) Tricatu, a herbal compound as immunomodulatory and anti-inflammatory agent in the treatment of rheumatoid arthritis - an experimental study. *Cell Immunol* 287:62-68.
- Nakhostin-Roochi B, Barmaki S, Khoshkharesh F, Bohlooli S (2011) Effect of chronic supplementation with methylsulfonylmethane on oxidative stress following acute exercise in untrained healthy men. *J Pharm Pharmacol* 63:1290-1294.
- Pattacini L, Boiardi L, Casali B, Salvarini C (2010) Differential effects of anti-TNF-alpha drugs on fibroblast-like synoviocyte apoptosis. *Rheumatology (Oxford)* 49:480-489.
- Phan TC, Xu J, Zheng MH (2004) Interaction between osteoblast and osteoclast: impact in bone disease. *Histol Histopathol* 19:1325-1344.
- Reuter S, Gupta SC, Phromnoi K, Aggarwal BB (2012) Thiocolchicoside suppresses osteoclastogenesis induced by RANKL and cancer cells through inhibition of inflammatory pathways: a new use for an old drug. *Br J Pharm* 165:2127-2139.
- Sabina EP, Rasool M (2008) An in vivo and in vitro potential of Indian ayurvedic herbal formulation Triphala on experimental gouty arthritis in mice. *Vascul Pharmacol* 48:14-20.
- Sandouk P, Bouvier d'Yvoire M, Chretien P, Tillement JP, Scherrmann M (1994) Single-dose bioavailability of oral and intramuscular thiocolchicoside in healthy volunteers. *Biopharm Drug Disp* 15:87-92.
- Sarban S, Kocyigit A, Yazar M, Isikan UE (2005) Plasma total antioxidant

- dant capacity, lipid peroxidation, and erythrocyte antioxidant enzyme activities in patients with rheumatoid arthritis and osteoarthritis. *Clin Biochem* 38:981-986.
- Shi F, Zhou D, Ji Z, Xu Z, Yang H (2015) Anti-arthritic activity of luteolin in Freund's complete adjuvant-induced arthritis in rats by suppressing P2X4 pathway. *Chem Biol Interac* 226:82-87.
- Soonawalla DF, Joshi N (2008) Efficacy of thiocolchicoside in Indian patients suffering from low back pain associated with muscle spasm. *J Indian Med Assoc* 106:331-335.
- Stamp LK, Khalilova I, Tarr JM, Senthilmohan R, Turner R, Haigh RC, Winyard PG, Kettle AJ (2012) Myeloperoxidase and oxidative stress in rheumatoid arthritis. *Rheumatology (Oxford)* 51:1796-1803.
- Umarkar AR, Bavaskar SR, Yewale PN (2011) Thiocolchicoside as muscle relaxant: a review. *Int J Pharm Biol Sci* 1:364-371.
- Xiao P, Hao Y, Zhu X, Wu X (2013) p53 Contributes to quercetin-induced apoptosis in human rheumatoid arthritis fibroblast-like synoviocytes. *Inflammation* 36:272-278.
- Zhang Y, Ren G, Guo M, Ye X, Zhao J, Xu L Qi J, Kan F, Liu M, Li D (2013) Synergistic effects of interleukin-1 β and interleukin-17A antibodies on collagen-induced arthritis mouse model. *Int Immunopharmacol* 15:199-205.